

Figure 1a: Proposed Guidelines for Imaging after Minor Head Trauma in Children <2
 From: Kupperman et al, Identification of children at very low risk of clinically-important brain injuries after head trauma: a prospective cohort study. Lancet, 2009

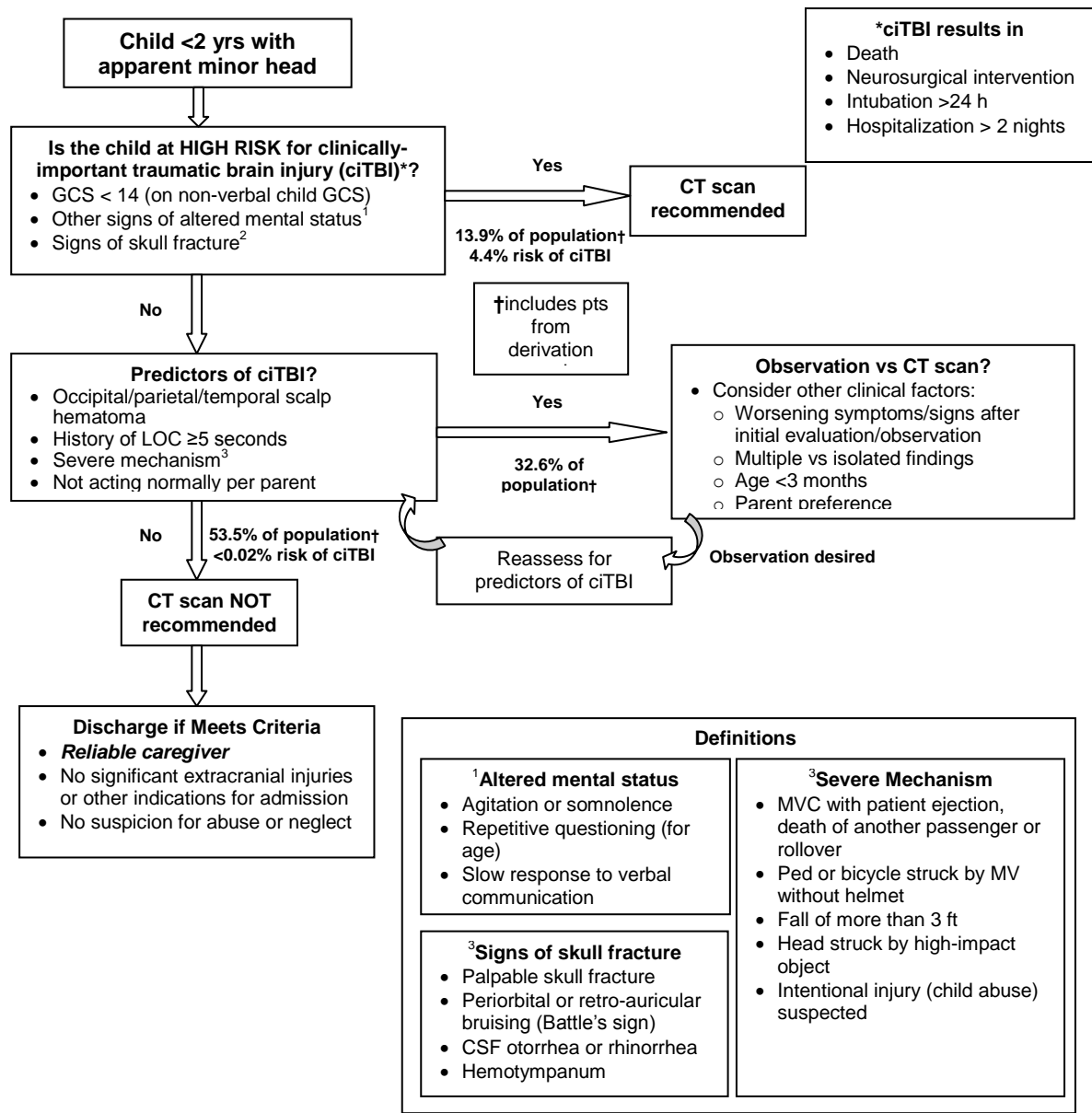


Figure 1b: Proposed Guidelines for Imaging after Minor Head Trauma in Children 2-18
 From: Kupperman et al, Identification of children at very low risk of clinically-important brain injuries after head trauma: a prospective cohort study. Lancet, 2009

